

# Collision Neoplasms of the Vermiform Appendix

Ana P. Melendez<sup>1</sup>, Xiaoli Chen<sup>2</sup>, Jesus Esquivel<sup>3\*</sup>

<sup>1</sup>Surgical Oncology Department, National Cancer Institute, Mexico, USA

<sup>2</sup>Pathology Department, Beebe Healthcare, Delaware, USA

<sup>3</sup>Surgical Oncology Department, Beebe Healthcare, Delaware, USA

Email: \*hipec.esquivel@gmail.com

**How to cite this paper:** Melendez, A.P., Chen, X.L. and Esquivel, J. (2022) Collision Neoplasms of the Vermiform Appendix. *Open Journal of Gastroenterology*, 12, 307-316.

<https://doi.org/10.4236/ojgas.2022.1210031>

**Received:** September 12, 2022

**Accepted:** October 21, 2022

**Published:** October 24, 2022

Copyright © 2022 by author(s) and Scientific Research Publishing Inc.

This work is licensed under the Creative

Commons Attribution International

License (CC BY 4.0).

<http://creativecommons.org/licenses/by/4.0/>



Open Access

## Abstract

Neoplasms of the vermiform appendix represent 1% of all gastrointestinal tumors, with epithelial and neuroendocrine histological subtypes being the most frequent. When two or more neoplasms with different components originate synchronically in the appendix with clear margin between them, it is called a collision tumor, with exceptional cases being reported in literature. The purpose is to present two new cases of collision tumors of the appendix and perform a review of the published literature. Two cases of an 82-year-old female and a 41-year-old male with collision tumors of the vermiform appendix are presented, with clinical presentation, radiological evaluation and surgical treatment exposed. Our results are compared with other published reports. In accordance with the other reported cases, both patients presented with low-grade appendiceal mucinous neoplasm (LAMN). Female patient with synchronous goblet cell carcinoma managed with a completion right colectomy and Hyperthermic intraperitoneal chemotherapy (HIPEC) and the other patient with well-differentiated neuroendocrine (NET) tumor managed with laparoscopic appendectomy without adjuvant treatment. Since very few cases have been reported, no diagnostic and therapeutic consensus and guidelines exist up to date. We agree that local, regional, and systemic therapies should be chosen according to the tumor that represents the worst prognosis.

## Keywords

Cytoreductive Surgery, HIPEC, Peritoneal Tumors, Collision Neoplasms

## 1. Introduction

Appendiceal neoplasms are uncommon, representing less than 0.5% to 1% of all gastrointestinal tumors [1]. Appendix tumors include a heterogenous group of

epithelial and nonepithelial neoplasms with the 2 main histopathologic types being, 1) neuroendocrine tumors (NETs) in 0.3% - 0.9% of appendectomies, followed by 2) epithelial neoplasms, in 0.2% - 0.3%, according to incidence reports [2] [3] [4]. Other rare neoplasms may be found, including an atypical hybrid tumor known as goblet cell carcinoma (formerly known as goblet cell carcinoids), which accounts for less than 5% of all appendiceal primary tumors [5].

The terms composite and collision tumors have been used interchangeably throughout the medical literature. Both composite and collision tumors involve two morphologically and immunohistochemically distinct neoplasms coexisting within a single organ [6] [7]. Composite tumors often arise from a common driver mutation that induces a divergent histology from a common neoplastic source and are characterized by histological cellular intermingling within the same tumor mass or in adjacent tumors with continued growth [7] [8] [9].

A collision tumor refers to the presence of two or more neoplasms of different histology that originate synchronously in one organ as a result of a bi-clonal transformation of two distinct cellular lines at the same time [10] [11] [12] [13]. Different hypotheses have emerged to elucidate the pathogenesis of collision tumors. The most accepted theory is the differentiation of two different cell types from a common progenitor cell. The second theory suggests that prolonged exposure and stimulus from carcinogens in the mucosal layer affect different regions of adjacent tissue and promote the coexistence of two or more distinct neoplasms [14] [15]. One important characteristic, is the absence of a transition zone, showing distinct borders between both lesions. Collision tumors, which are rare but well documented, can be composed of two benign tumors, a benign and a malignant tumor, or two malignant tumors [7] [8].

This infrequent phenomenon has been observed in almost every organ, including the gastrointestinal system. In one of the few existing series published, authors found that anatomical location from most to least frequent was the stomach (37.7%), the esophagus (32%), the large intestine (26%), and the small intestine (3.7%), respectively [14] [15] [16].

The first published series describing collision tumors of the vermiform appendix was in 1995 by Carr *et al.* [17] from the USA-AFIP (Armed Forces Institute of Pathology 1862-2011) reporting 13 patients with dual carcinoid and epithelial neoplasia of the appendix, with predominance of insular subtype and mucinous cystadenocarcinoma. Since then, less than 14 additional cases have been reported in the English literature (**Table 1**). All cases demonstrate a similar histologic pattern, showing predominance for the concomitance of mucinous neoplasms and neuroendocrine tumors [18] [19] [20] [21] [22].

With so few cases reported, well defined strategies to determine the optimal treatment of these patients are lacking. Debate exists whether management should be centered on the tumor with the highest pattern of invasion or if it should be based on the most aggressive histology present.

The purpose of this study is to provide an overview of collision tumors of the

**Table 1.** Summary 29 case reports in literature collision tumors of the vermiform appendix.

Author/Year	N° cases	Sex/Age (years)	Presentation	Histology	Treatment	Follow-up (months)
Carr <i>et al.</i> 1995 [17]	13	F (53%) 49 (22 - 92)	Acute appendicitis (30%)	Mucinous cystadenocarcinoma (46.1%)/Carcinoid (76%)	Not specified	OS 57 months: 100% (Only 7 patients followed)
Alsaad <i>et al.</i> 2009 [18]	1	F 46	Acute right iliac fossa pain	Goblet cell carcinoma/Mucinous cystadenoma	Right colectomy	Not specified
Singh <i>et al.</i> [19] 2010	1	M 52	Chronic pain in right lower quadrant, palpable mass	Carcinoid/Mucinous adenocarcinoma	Right colectomy + omental deposit excision/Adjuvant ChT (6 months)	DFS 6 months: Peritoneal carcinomatosis, liver, omentum and rectus muscle metastases. OS: 14 months
Dellaportas <i>et al.</i> [20] 2014	1	F 57	Mass in right iliac fossa	Well-differentiated NET/mucinous cystadenoma	Laparoscopic appendectomy and right oophorectomy + complementary right colectomy	DFS 12 months
Villa <i>et al.</i> [21] 2021	10	F (63.6%) 37.8 (23 - 60)	Acute appendicitis (63.6%)	LAMN/ANET	Appendectomy (90%)/Complementary right colectomy (63.6%)/CRS + HIPEC (45.5%)	DFS 18.5 months (6 - 60) 1 (9.09%) perihepatic and pleural recurrence
Ruiz <i>et al.</i> [22] 2021	1	M 54	Acute right iliac fossa pain	LAMN/well-differentiated ANET	Laparoscopic appendectomy and partial cecectomy	Not specified
Melendez, Esquivel <i>et al.</i> 2022	2	F 82	Acute right iliac fossa pain	Goblet cell adenocarcinoma/LA MN	Laparoscopic appendectomy/ Complementary right colectomy + CRS + HIPEC/Adjuvant ChT (6 months)	Starting surveillance
		M 41	Acute right iliac fossa pain	Goblet cell adenocarcinoma/LA MN	Laparoscopic appendectomy	DFS 6 months

vermiform appendix, discuss the hallmark of clinical, radiographic, and pathological presentations of two new cases, and conduct an analysis of the published literature. In addition, we will present our suggestions on how to counsel these patients regarding treatment.

## 2. Material and Methods

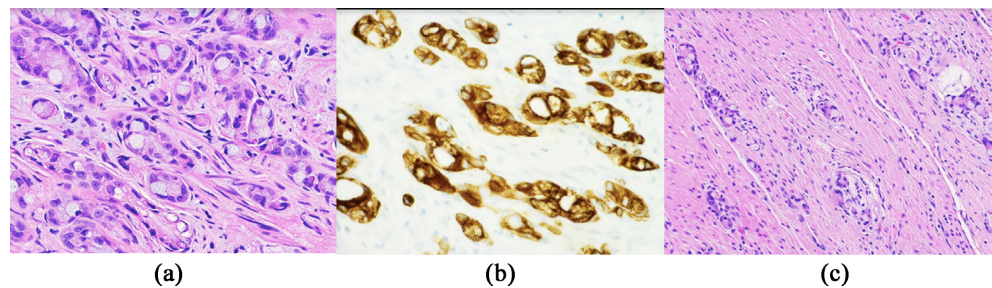
### 2.1. Patient N° 1

An 82-year-old female presented with signs and symptoms of acute appendicitis. A CT scan of the abdomen and pelvis was compatible with acute appendicitis with an associated peri appendiceal collection. A laparoscopic appendectomy

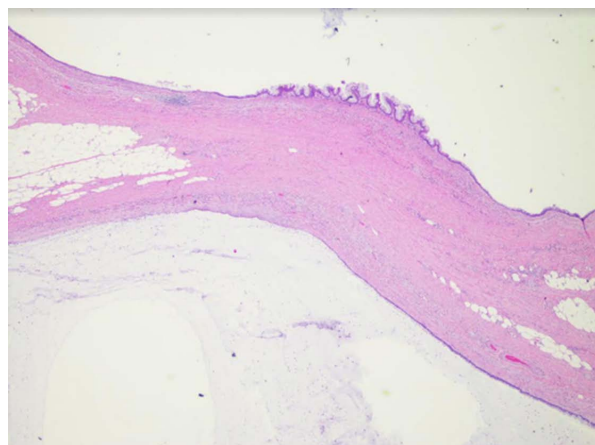
was performed in September 2021 with intraoperative findings of mucinous material localized in the pelvis and right flank, associated with an enlarged and edematous appendix.

### Pathology Description

Grossly, the appendix measured 5.6 cm in length by 1.0 to 1.8 cm in diameter with attached mesoappendix. Located 0.9 cm from the proximal margin is a transmural defect (0.5 cm in diameter) with leaking clear mucinous material. Microscopically, the low-grade appendiceal mucinous neoplasm (LAMN) is seen throughout the luminal epithelium from the distal tip to approximately 1 cm from the proximal margin. The acellular mucin invades the visceral peritoneum associated with perforation (pT4a). Additionally, a moderately differentiated invasive adenocarcinoma with goblet cell morphology (small, compressed nuclei with intracytoplasmic mucin) was identified only microscopically (**Figure 1** and **Figure 2**). It arises from the appendiceal orifice, infiltrating circumferentially and distally, mostly through the muscularis propria. The tumor extends to the subserosa (pT3). Separate borders between both neoplasms are observed. The LAMN tumor has only infiltrating acellular mucin seen, without infiltrating glandular component.



**Figure 1.** (a) Circumferential infiltration of the appendiceal wall by small tubules and clusters of tumor cells as well as single cells with goblet cell morphology at the appendiceal orifice. H & E 40 $\times$ . (b) The tumor cells are diffusely positive for CK20 (shown here) and CDX2 and are negative for CK7 by immunohistochemistry. 20 $\times$ . (c) Similar infiltrating tumor cells with goblet cell morphology are present within the cecal wall in the subsequent right hemicolectomy specimen. H & E 20 $\times$ .



**Figure 2.** Low-grade appendiceal mucinous neoplasm at the distal tip of the appendix. H & E.

## 2.2. Patient N° 2

A 41-year-old male presented to the emergency room complaining of anorexia, low grade fever and localized right lower quadrant abdominal pain. A CT scan of the abdomen and pelvis confirmed the clinical suspicion of acute appendicitis. A laparoscopic appendectomy was performed in November 2021 without incidents and the patient was sent home.

### Pathology Description

Grossly, the appendix measured 7.5 cm in length by 0.7 to 1.5 cm in diameter with attached mesoappendix. The lumen is filled with clear mucinous material, which appears to extend into the surrounding mesoappendix. Microscopically, the dilated lumen is filled with mucin and is lined by glandular epithelium with low-grade atypia, consistent with low-grade appendiceal mucinous neoplasm (LAMN). The acellular organizing mucin is present at the serosa (pT4a). Approximately 90% of the appendix is involved by LAMN from the distal tip to the proximal portion. A 5 mm well-differentiated neuroendocrine tumor, WHO grade 1, was incidentally identified in the submucosa microscopically near the proximal margin but was separated from the proximal portion of the LAMN with a distinct border. Immunohistochemical stains were positive for pancyokeratin, synaptophysin and chromogranin, with a low Ki-67 proliferation index (<5%) (**Figure 3**).

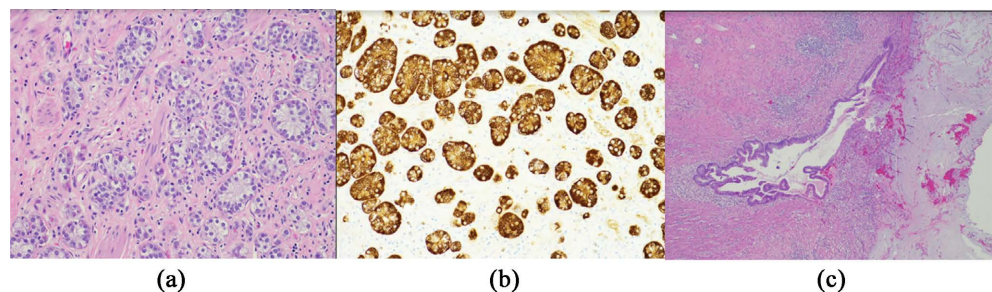
## 3. Ethical Statement

This review was conducted in accordance with the amended Declaration of Helsinki, and the guidelines of our local institutional review board at Beebe's Ethics Committee.

## 4. Results

### 4.1. Subsequent Management Patient N° 1

Appendiceal tumors are associated with a higher chance of having colonic polyps.



**Figure 3.** (a) Well-differentiated goblet cell carcinoma, present in submucosa. Uniform glands with clear to granular cytoplasm, round nuclei, and small nucleoli. H & E 20×. (b) The tumor cells are diffusely positive for neuroendocrine markers of chromogranin (shown here) and synaptophysin by immunohistochemistry. 20×. (c) Low-grade appendiceal mucinous neoplasm: An irregular neoplastic glandular structure with low-grade cytologic atypia in the subserosa and acellular organizing mucin at the serosa. H & E 4×.



As the patient had not had a recent colonoscopy, one was performed prior to her next treatment. The colonoscopy was negative. The patient was discussed at our multidisciplinary tumor board and because of her T3 high grade tumor (goblet cell carcinoma), the recommendation was to proceed with a right colectomy. Due to the presence of extra-appendiceal mucin and the fact that she was going to have surgery, a laparoscopy omentectomy and hyperthermic intraperitoneal chemotherapy (HIPEC) were also recommended.

The histopathologic report identified residual microscopic foci of infiltrating goblet cell carcinoma within the cecal wall adjacent to the previous surgical site in the subsequent right hemicolectomy specimen. No primary cecal tumor is identified. The tumor was confirmed as goblet cell carcinoma of an appendiceal primary (WHO Classification of Tumors 2019) based on morphology and immunohistochemistry. Fourteen benign lymph nodes were identified (pN0).

The patient had an excellent postoperative recovery. She was considered a candidate for adjuvant chemotherapy with Capecitabine for 6 months. As of March 2022, she is currently under surveillance, with no clinical or radiological evidence of recurrence.

#### **4.2. Subsequent Management Patient N° 2**

The patient had a colonoscopy to rule out additional pathology. The study was negative for polyps. No additional surgical interventions were recommended. He is under surveillance and will be followed with a peritoneal metastases protocol MRI every 6 months for two years and then every year for three more years.

### **5. Discussion**

Neoplasms of the vermiform appendix occur infrequently. Their incidence is estimated at 1% of the incidence of colorectal cancers. This is surprising as the entire surface area of the appendiceal mucosa is far less than 1% of the surface area of the colon and rectum. The two most common histological types include neuroendocrine tumors and epithelial mucinous neoplasms [23] [24] [25].

A collision tumor refers to the presence of two or more separated neoplasms of different histology that originate synchronously in one organ as a result of a bi-clonal transformation of two distinct cellular lines at the same time. Different hypotheses have emerged to elucidate the pathogenesis of collision tumors. The most accepted theory is the differentiation of two different cell types from a common progenitor cell. And the second one, the prolonged exposure and stimulus from carcinogens in the mucosal layer affecting different regions of adjacent tissue and promoting the coexistence of two or more distinct neoplasms. This latter theory could be more significant in the appendix as the appendix is a tubular structure with a blind end which would facilitate a prolonged exposure to retained intestinal carcinogens [4] [12] [13].

There are 25 cases of LAMN/mucinous cystadenocarcinoma with ANET/carcinoid, 1 case of LAMN/mucinous cystadenocarcinoma with goblet cell carci-

noma, and 1 case of mucinous adenocarcinoma with carcinoid out of the 27 case reports in the literature (**Table 1**). One of our two case reports confirms the most common histologic type of collision tumor (LAMN/mucinous cystadenocarcinoma with ANET/carcinoid) and the other case report of ours contributes to the second common one (LAMN/mucinous cystadenocarcinoma with goblet cell carcinoma). The histologic types of collision tumors in the vermiform appendix are consistent with the two most common histologic types of individual appendiceal tumors (neuroendocrine tumor and epithelial mucinous neoplasm) [24] [25]. No poorly differentiated neuroendocrine carcinomas (small cell and large cell neuroendocrine carcinomas) have been reported in the appendiceal collision tumors in the literature yet. Two distinct histologic epithelial tumors with no neuroendocrine component nor related to neuroendocrine component (goblet cell carcinoma) have not been reported in the appendiceal collision tumors, either (for example, LAMN and medullary carcinoma).

How to counsel a patient diagnosed with an appendiceal neoplasms remains an unmet need in oncology. Since very few cases have been reported, no diagnostic and therapeutic consensus has been achieved. There are no National Comprehensive Cancer Network (NCCN) guidelines [26] [27]. Treatment is based on existing recommendations for individual primary vermiform appendix tumors [18] [19] [20] [21] [28].

Due to the overall good prognosis of many of these patients, a prospective randomized clinical trial with a risk stratified cohort of patients would require substantial accrual and a very long follow up, making such a study not feasible. Therefore, a decision-analysis modeling approach based on clinical and pathological variables commonly described by the healthcare providers seeing these patients is preferred.

With over 20 years of experience treating appendiceal tumors, we have identified that the two most important prognostic indicators are the grade of the tumor and the extent of peritoneal dissemination [29] [30] [31] [32]. As such, when a collision tumor of the vermiform appendix is identified, we suggest proposing a treatment plan based on the tumor with the most aggressive histology. In those patients without peritoneal dissemination, a simple appendectomy would be enough for small, well-differentiated NETs with a low Ki67 percentage and for low grade appendiceal mucinous neoplasms (LAMN) even if they are T4a lesions. A completion right colectomy would be recommended for those patients whose primary tumor has a potential for lymph node involvement, like in larger and proximal carcinoids, high-grade adenocarcinomas, or goblet cell carcinomas. If there is evidence of peritoneal dissemination, then the extent of the peritoneal dissemination along with the grade of the tumor would determine if a patient should go directly to cytoreductive surgery and HIPEC like in LAMNs, even with extensive peritoneal implants, and well-differentiated mucinous adenocarcinomas with a low peritoneal cancer index (PCI), or if a patient should receive first neo-adjuvant systemic therapies, like in a signet ring cell carcinoma

with a very high PCI.

## 6. Conclusions

The presence of a collision tumor in the vermiform appendix represents a challenge in the diagnosis and management of this pathology; however, we agree with other authors in guiding definitive surgical management according to the tumor that represents the worst prognosis in consistence with the high-risk characteristics of each neoplasm. This also applies for choosing the best adjuvant management with local, regional, and systemic therapies according to each individual case.

Most of these cases will present with none to limited peritoneal dissemination. For this reason, when additional surgery and/or Hyperthermic intraperitoneal chemotherapy (HIPEC), are indicated, minimal invasive approaches, including laparoscopic cytoreductive surgery and HIPEC should be considered in favor of open procedures.

## Acknowledgements

The author(s) received no financial support for the research, authorship, and/or publication of this article.

## Conflicts of Interest

The authors declare no conflicts of interest regarding the publication of this paper.

## References

- [1] Marmor, S., Portschy, P.R., Tuttle, T.M. and Virnig, B.A. (2015) The Rise in Appendiceal Cancer Incidence: 2000-2009. *Journal of Gastrointestinal Surgery*, **19**, 743-750. <https://doi.org/10.1007/s11605-014-2726-7>
- [2] Turaga, K.K., Pappas, S.G. and Gamblin, T.C. (2012) Importance of Histologic Subtype in the Staging of Appendiceal Tumors. *Annals of Surgical Oncology*, **19**, 1379-1385. <https://doi.org/10.1245/s10434-012-2238-1>
- [3] Nutu, O.A., Quinto, A.A.M., Municio, A.M., *et al.* (2017) Mucinous Appendiceal Neoplasms: Incidence, Diagnosis and Surgical Treatment. *Cirugía Española (English Edition)*, **95**, 321-327. <https://doi.org/10.1016/j.cireng.2017.07.011>
- [4] Al-Balas, H., Al-Saffar, R.S., Al-Balas, M., *et al.* (2021) Unusual Histopathological Findings in Appendectomy Specimens with Clinical Diagnosis of Acute Appendicitis: A Retrospective Cohort Analysis. *Annals of Medicine and Surgery*, **69**, Article ID: 102720. <https://doi.org/10.1016/j.amsu.2021.102720>
- [5] Yozu, M., Johncilla, M.E., Srivastava, A., *et al.* (2018) Histologic and Outcome Study Supports Reclassifying Appendiceal Goblet Cell Carcinoids as Goblet Cell Adenocarcinomas and Grading and Staging Similarly to Colonic Adenocarcinomas. *The American Journal of Surgical Pathology*, **42**, 898-910. <https://doi.org/10.1097/PAS.0000000000001056>
- [6] Murthaiah, P., Truskinoskt, A.M., Shah, S. and Dudek, A.Z. (2009) Collision Tumor versus Multiphenotypic Differentiation: A Case of Carcinoma with Features of Co-



Ionic and Lung Primary Tumors. *Anticancer Research*, **29**, 1495-1498.

- [7] Manier, J.W. and Reyes, C.N. (1974) Collision Tumor of the Stomach. Report of Two Cases. *Gastroenterology*, **67**, 1011-1015. [https://doi.org/10.1016/S0016-5085\(19\)32758-1](https://doi.org/10.1016/S0016-5085(19)32758-1)
- [8] Miyamoto, R., Kikuchi, K., Uchida, A., *et al.* (2018) Collision Tumor Consisting of a Colorectal Adenocarcinoma and Dissemination of a Gastric Adenocarcinoma. *SAGE Open Medical Case Reports*, **6**, 1-5. <https://doi.org/10.1177/2050313X17751839>
- [9] Jang, K.S., Lee, W.M., Kim, Y.J. and Cho, S.H. (2012) Collision of Three Histologically Distinct Endometrial Cancers of the Uterus. *Journal of Korean Medical Science*, **27**, 89-92. <https://doi.org/10.3346/jkms.2012.27.1.89>
- [10] Sugarbaker, P.H., Ben-Yaacov, A., Hazzan, D. and Nissan, A. (2020) Synchronous Primary Neuroendocrine and Mucinous Epithelial Tumors Present in the Same Appendix. Case Report of 2 Patients. *International Journal of Surgery Case Reports*, **67**, 76-79. <https://doi.org/10.1016/j.ijscr.2020.01.022>
- [11] Ekinci, N., Gün, E., Avci, A. and Er, A. (2021) Coexistence of Low-Grade Mucinous Neoplasm and Carcinoid (Collision Tumor) within Multiple Appendiceal Diverticula: A Case Report. *Turkish Journal of Surgery*, **37**, 303-306. <https://doi.org/10.47717/turkjsurg.2021.3877>
- [12] Michalinos, A., Constantinidou, A. and Kontos, M. (2015) Gastric Collision Tumors: An Insight into Their Origin and Clinical Significance. *Gastroenterology Research and Practice*, **2015**, Article ID: 314158. <https://doi.org/10.1155/2015/314158>
- [13] Furlan, D., Cerutti, R., Genasetti, A., *et al.* (2003) Microallelotyping Defines the Monoclonal or the Polyclonal Origin of Mixed and Collision Endocrine-Exocrine Tumors of the Gut. *Laboratory Investigation*, **83**, 963-971. <https://doi.org/10.1097/01.LAB.0000079006.91414.BE>
- [14] Bhattacharya, A., Saha, R., Biswas, J. and Ghosh, B. (2012) Collision Tumors in the Gastrointestinal Tract: A Rare Case Series. *International Medical Case Reports Journal*, **5**, 73-77. <https://doi.org/10.2147/IMCRJ.S35818>
- [15] Karkouche, R., Bachet, J.-B., Sandrini, J., *et al.* (2012) Colorectal Neuroendocrine Carcinomas and Adenocarcinomas Share Oncogenic Pathways. A Clinico-Pathologic Study of 12 Cases. *European Journal of Gastroenterology & Hepatology*, **24**, 1430-1437. <https://doi.org/10.1097/MEG.0b013e3283583c87>
- [16] Hosseini, M. and Ronquillo, N. (2020) Goblet Cell Adenocarcinoma: Concepts and Updates. *Diagnostic Histopathology*, **27**, 69-74. <https://doi.org/10.1016/j.mpdhp.2020.11.003>
- [17] Carr, N.J., Remotti, H. and Sobin, L.H. (1995) Dual Carcinoid/Epithelial Neoplasia of the Appendix. *Histopathology*, **27**, 557-562. <https://doi.org/10.1111/j.1365-2559.1995.tb00327.x>
- [18] Alsaad, K.O., Serra, S. and Chetty, R. (2009) Combined Goblet Cell Carcinoid and Mucinous Cystadenoma of the Vermiform Appendix. *World Journal of Gastroenterology*, **15**, 3431-3433. <https://doi.org/10.3748/wjg.15.3431>
- [19] Singh, N.G., Mannan, A.A.S.R., Kahvic, M. and Nur, A.M. (2011) Mixed Adenocarcinoma-Carcinoid (Collision Tumor) of the Appendix. *Medical Principles and Practice*, **20**, 384-386. <https://doi.org/10.1159/000324870>
- [20] Dellaportas, D., Vlahos, N.P., Polymeneas, G., *et al.* (2014) Collision Tumor of the Appendix: Mucinous Cystadenoma and Carcinoid: A Case Report. *Chirurgia*, **109**,

843-845.

- [21] Villa, M., Sforza, D., Siragusa, L., *et al.* (2021) A Low-Grade Appendiceal Mucinous Neoplasia and Neuroendocrine Appendiceal Collision Tumor: A Case Report and Review of the Literature. *The American Journal of Case Reports*, **22**, e927876. <https://doi.org/10.12659/AJCR.927876>
- [22] Ruiz, S.G., Geraghty, F., Padron, D., *et al.* (2021) The Appendix: A Rare Case of an Appendiceal Collision Tumor. *Cureus*, **13**, e17050. <https://doi.org/10.7759/cureus.17050>
- [23] Glasgow, S.C., Gaertner, W., Stewart, D., *et al.* (2019) The American Society of Colon and Rectal Surgeons, Clinical Practice Guidelines for the Management of Appendiceal Neoplasms. *Diseases of the Colon & Rectum*, **62**, 1425-1438. <https://doi.org/10.1097/DCR.0000000000001530>
- [24] Sholi, A.N., Gray, K.D. and Pomp, A. (2019) Management and Outcome of an Appendiceal Collision Tumour Composed of Neuroendocrine and Mucinous Neoplasms. *BMJ Case Reports*, **12**, e229414. <https://doi.org/10.1136/bcr-2019-229414>
- [25] Carr, N.J., Bibeau, F., Bradley, R.F., *et al.* (2017) The Histopathological Classification, Diagnosis, and Differential Diagnosis of Mucinous Appendiceal Neoplasms, Appendiceal Adenocarcinomas and Pseudomyxoma Peritonei. *Histopathology*, **71**, 847-858. <https://doi.org/10.1111/his.13324>
- [26] Hoehn, R., Rieser, C.J., Choudry, M.H., *et al.* (2021) Current Management of Appendiceal Neoplasms. *American Society of Clinical Oncology Educational Book*, **41**, 118-132. [https://doi.org/10.1200/EDBK\\_321009](https://doi.org/10.1200/EDBK_321009)
- [27] Schizas, D., Katsaros, I., Michalinos, A., *et al.* (2018) Collision Tumors of the Gastrointestinal Tract: A Systematic Review of the Literature. *Anticancer Research*, **38**, 6047-6057. <https://doi.org/10.21873/anticancer.12955>
- [28] Pape, U.-F., Niederle, B., Costa, F., *et al.* (2016) ENETS Consensus Guidelines for Neuroendocrine Neoplasms of the Appendix (Excluding Goblet Cell Carcinomas). *Neuroendocrinology*, **103**, 144-152. <https://doi.org/10.1159/000443165>
- [29] Shaib, W.L., Assi, R., Shamseddine, A., *et al.* (2017) Appendiceal Mucinous Neoplasms: Diagnosis and Management. *The Oncologist*, **22**, 1107-1116. <https://doi.org/10.1634/theoncologist.2017-0081>
- [30] Shaib, W., Krishna, K., Kim, S., *et al.* (2016) Appendiceal Neuroendocrine, Goblet and Signet-Ring Cell Tumors: A Spectrum of Diseases with Different Patterns of Presentation and Outcome. *Cancer Research and Treatment*, **48**, 596-604. <https://doi.org/10.4143/crt.2015.029>
- [31] da Silva Abreu, R.P.N. (2018) Appendiceal Neuroendocrine Tumors: Approach and Treatment. *Journal of Coloproctology*, **38**, 337-342. <https://doi.org/10.1016/j.jcol.2018.05.010>
- [32] Dehal, A., Smith, J.J. and Nash, G.M. (2016) Cytoreductive Surgery and Intraperitoneal Chemotherapy: An Evidence-Based Review-Past, Present, and Future. *Journal of Gastrointestinal Oncology*, **7**, 143-157.